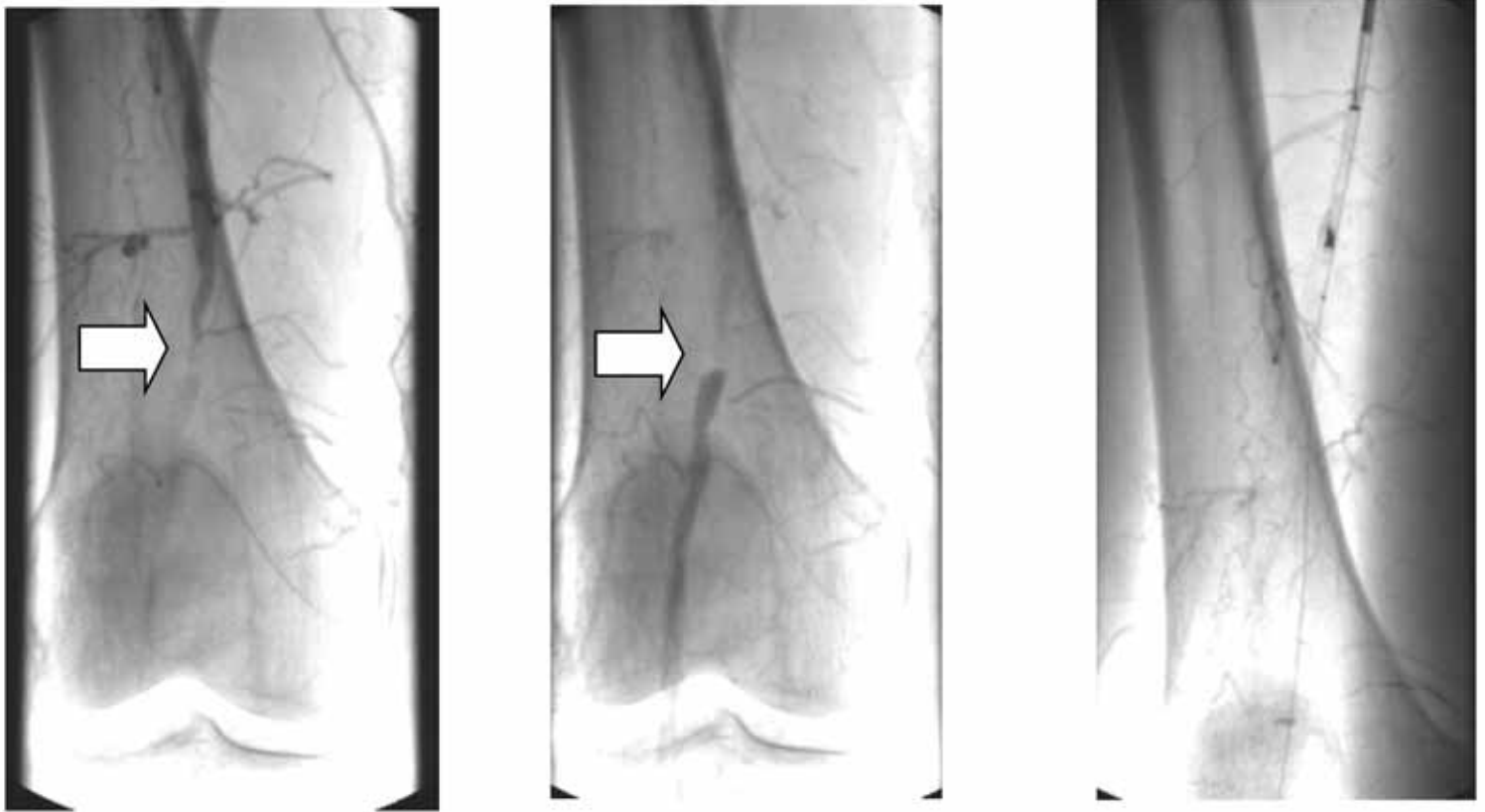


83YO FEMALE WITH SEVERE RIGHT CALF CLAUDICATION



The first two images reveal a focal total occlusion of the superficial femoral artery. The third image shows the Foxhollow Silverhawk Atherectomy catheter above the stenosis. The final image shows the artery after being “hawked” with a SS+ and LS-F cutter. The patient had strong DP and PT pulses at the end of the case and was discharged on the same day.

